

Review

Resurgence of yaws in Benin: Four confirmed cases in the district of Zè, Southern Benin

Adjimon Gilbert Ayélo^{1*}, Bérénice K. Esthelle Degboe², Yves Thierry Barogui³, Inès Cica Gomido¹, Anita Carolle Wadagni⁴, Christelle d'Almeida⁵, Gabriel Diez⁶, Jean Gabin Houezo⁴, Johnson Roch Christian⁷ and Sopoh Ghislain Emmanuel^{1,8}

¹Centre de Dépistage et de Traitement de l'Ulcère de Buruli d'Allada, Allada, Benin.

²Unité d'Enseignement et de Recherche en Dermatologie Vénérologie, Faculté des Sciences de la Santé Cotonou, Benin.

³Centre de Dépistage et de Traitement de l'Ulcère de Buruli de Lalo, Lalo, Benin.

⁴Direction de la Coordination du Programme National de Lutte contre la Lèpre et l'Ulcère de Buruli, Ministry of Health, Benin.

⁵Hôpital d'Instruction des Armées-Centre Hospitalier Universitaire, Cotonou, Benin.

⁶Fondation ANESVAD, Spain.

⁷Centre Interfacultaire de Formation et de Recherche en Environnement pour le Développement Durable, Abomey Calavi, Bénin.

⁸Institut Régional de Santé Publique Comlan Alfred Quenum, Ouidah, Bénin.

Received 8 November, 2019; Accepted 11 December, 2019

Yaws is an infectious neglected tropical disease (NTD) caused by the *Treponema pallidum pertenu* which is highly contagious and transmitted through direct contact with an infected person. It mainly affects skin, bone and cartilage and predominantly in children under 15 years of age. The last cases in Benin were documented in 1982 in the districts of Adjohoun, Bonou and Dangbo in Southern Benin. In line with the global strategy of yaws eradication, yaws surveillance had been reactivated in Benin in 2012 through the National Control Programme of Leprosy and Buruli Ulcer (PNLLUB). Following two yaws prevalence surveys among schoolchildren in 2012 and 2013 in Southern Benin, that failed to detect yaws case, the PNLLUB adopted in 2016 field mass medical consultation campaign as an integrated screen and case management strategy for skin NTDs. During the field mass medical consultation organized in five districts in Southern Benin within October – December 2018, four yaws cases had been confirmed in two villages in the district of Zè. These are the first yaws cases confirmed in Benin since 1982 and thus confirm the re-emergence of yaws in Benin.

Key words: Yaws, reemerging infectious diseases, Benin.

INTRODUCTION

Yaws is an infectious neglected tropical disease (NTD) caused by the *Treponema pallidum pertenu*, closely

related to syphilis. Its only reservoir is in human and especially in children aged of 2 to 15 years (Mitjà et al.,

*Corresponding author. E-mail: gilvinos@yahoo.fr.

2013; Marks et al., 2014). Yaws is the most prevalent of the endemic treponemal diseases (Marks et al., 2014; World Health Organization, 2018d). It is a highly contagious disease, transmitted through direct contact with an infected person. Indeed, yaws infection is spread by skin to skin contact when bacteria from a lesion enter via a breach, such as a scratch or an insect bite, in the skin of the recipient (Mitjà et al., 2013; Marks et al., 2014). The disease can be clustered in households, but transmission also happens between children in the community, schools, and other public places (Mitjà et al., 2013).

The disease occurs in warm humid environments mainly in forested tropical regions in Africa and Asia. It predominantly affects children under 15 years of age and affects skin, bone and cartilage (Knauf et al., 2013; Mitjà et al., 2013; Marks, 2016). Its spread is facilitated by lack of hygiene, promiscuity, overpopulation, and the absence of health centers or the remoteness from health centers (Mitjà et al., 2015; World Health Organization, 2018a, b, c, d).

The clinical manifestation of yaws arise in three distinct stages. The primary yaws is characterized by an erythematous lesion at the site of inoculation after an incubation period of 9-90 days and which may break down to form an ulcerating plaque over a period of 1-2 weeks evolution. The secondary yaws is characterized by a variety of skin manifestation including multiple ulcerative lesions, macular and hyperkeratotic lesions on the palms and soles. Bone lesions are commonly osteoperiostitis affecting fingers or long bones and resulting in bone pain and swelling. Tertiary yaws, rarely seen nowadays, may manifest as gummatous nodules causing tissue necrosis, a destructive osteitis. If not treated, yaws can progress to destructive lesions of the skin, soft tissues and bones (Mitjà et al., 2013; Marks et al., 2014; Marks, 2016).

Yaws is serologically indistinguishable from syphilis and the other endemic treponemal diseases. The biological confirmation of yaws uses the same serological tests for syphilis. Serological diagnosis of clinically active yaws requires detection of the two distinct sets of antibodies, one against treponemal antigens and one against non-treponemal antigens. The non-treponemal agglutination tests, rapid plasma reagin and venereal disease research laboratory, are positive in untreated cases (Mitjà et al., 2013; Fitzpatrick et al., 2017). Rapid diagnosis tests are now available for screening and confirming yaws cases. The rapid syphilis tests are used to detect treponemal antibodies, while the "DPP[®] Syphilis screen and confirm assay" (Chembio, Medford, NY, USA) tests detect both treponemal and non-treponemal antibodies. The DPP[®] Syphilis screen and confirm assay" (Chembio, Medford, NY, USA) is used to confirm active yaws cases (Fitzpatrick et al., 2017).

Benzathine benzyl penicillin in one intramuscular dose

has been used to treat yaws in 1948 and has been the mainstay of yaws treatment and eradication efforts for the past years. Recent research on yaws treatment has proved the effectiveness of a single dose of oral azithromycin as intramuscular benzathine benzyl penicillin in the treatment of yaws (Mitjà et al., 2012; Mitjà, Asiedu and Mabey, 2013).

From 1952-1964, the World Health Organization (WHO) in collaboration with the United Nations International Children's Emergency Fund (UNICEF) conducted a mass treatment campaign in 46 endemic countries, including Benin, which reduced the incidence of the disease by 95% worldwide. But yaws reappeared in recent years in Africa, Asia and the western pacific. In fact, from 2008-2013, 11 of 13 countries known to be endemic for yaws notified cases to the WHO. The data on yaws was not available for Benin as yaws was not a disease on surveillance in Benin (Asiedu et al., 2008; World Health Organization, 2008, 2012).

The southern part of Benin was known as a traditional foci of yaws in the 1950s. From 1955-1958, yaws was mesoendemic with a clinical prevalence of 7.5%. Following the mass treatment campaigns organized by WHO and UNICEF between 1958 and 1962 in Benin, this prevalence decreased to 0.7% by 1964. During the 1970s, yaws resurged in Benin as in other countries that had benefitted from the mass treatment campaign. In fact, Benin reported to WHO 6,880 and 10,445 cases of yaws respectively in 1972 and 1979 (Baudon and Houssou, 1984). The last yaws cases in Benin were documented in 1982. Indeed, a yaws prevalence survey conducted in (1982) in schoolchildren of the districts of Dangbo, Adjohoun and Bonou, all located in southern Benin, revealed a 1.7% clinical prevalence of yaws among the schoolchildren versus a serological yaws prevalence of 16.3% (Baudon and Houssou, 1984). Despite the results of this survey confirming yaws resurgence in Benin, any action was taken to eradicate the disease and yaws was not a disease on surveillance.

Based on the India's experience in the eradication of yaws (Narain et al., 2015; World Health Organization, 2015) and the proven effectiveness of a single dose of oral Azithromycin (Mitjà et al., 2012) for yaws treatment, WHO met in Morges in 2012 and issued a global strategy of yaws eradication targeted to 2020 (World Health Organization, 2012). Accordingly, the PNLLUB which is in charge of Buruli ulcer and leprosy control in Benin, reactivated the surveillance of yaws in 2012 through the Buruli Ulcer Center (CDTUB) in Benin. Following two yaws prevalence surveys among schoolchildren in 2012 and 2013 in two health districts in South of Benin which failed to detect yaws case (Mitjà et al., 2015), the PNLLUB adopted in 2016, field mass medical consultation campaigns as an integrated screen and case management strategy for skin NTDs (Barogui et al., 2018). Two field medical consultation campaigns were

organized in five districts of the Department of Atlantique in Southern Benin in 2017 and 2018 including respectively 13 and 15 subdistricts. Populations in the concerned subdistricts were previously informed of the date of the field mass medical consultation in their respective subdistricts. The medical consultation team from Buruli Ulcer Treatment Center of Allada with a dermatologist stayed at the public health center of the subdistrict to attend to people from different villages of the subdistrict. The medical consultation and treatment given to the patients were free of charge. During the field mass consultation campaigns, children under 15 years of age were systematically screened for yaws using the treponemal rapid diagnostic test. The campaigns organized in 2016 in the Department of Couffo (Barogui et al., 2018) and in 2017 in the Department of Atlantique failed to detect yaws case. In 2018, 1837 people were attended to in the five districts covered by the activity and 4 yaws cases were detected in 2 villages of the district of Zè.

The District of Zè is located in the South of Benin, between 6°32 and 6°87 North latitude and between 2°13 and 2°26 East longitude. It covers an area of 653 km² with a population estimated for 123,424 inhabitants in 2018. It is bordered in the north with the districts of Toffo and Zogbodomey, in the south with the districts of Abomey Calavi and Tori-Bossito, in the east with the districts of Adjohoun and Bonou, and in the west with the district of Allada. The district of Zè is made up of 11 subdistricts with a total of 101 villages which include Agonzounkpa in the subdistrict of Dawé and Gandaho in the subdistrict of Dodji Bata where the four cases of yaws were detected (Figure 1). The district of Zè is known as co-endemic for Buruli ulcer, leprosy and mycetoma.

This case report describes the four cases of yaws detected in 2018 in the district of Zè during the field mass medical consultation campaign in the Department of Atlantique, southern Benin.

CASE PRESENTATION

Case 1

Case 1 was 4-years old, male, from the Aizo ethnic group, who lived in the village of Gandaho in the Subdistrict of Dodji Bata in Zè, with his paternal grandmother. He was 93 cm tall, weighed 10 kg and was not schooled. He was accompanied by his grandmother for skin lesions that had been growing for about 5 months on his right upper limb. These lesions were painless, did not itch and were not accompanied by fever. There was no notion of taking medication or prior medical consultation. However, there was notion of an unsuccessful use of phytotherapy. According to his grandmother, he was infected by the case 2 below with

whom he shared the same home. The physical examination revealed multiple papillomas clustered on the right thumb, on the right wrist, on the forearm and on the right shoulder (Figure 2a). The treponemal rapid diagnostic test performed (RDT) was positive. The rapid diagnostic double test (treponemal and non-treponemal) using “DPP[®] Syphilis Screen and Confirm Assay” was also positive thus confirming clinical active yaws case (Figure 2b). The rapid plasma reagin (RPR) test carried out on venous blood samples at the laboratory of CDTUB Allada was positive. He was treated promptly with 500 mg of oral Azithromycin and full recovery was achieved after 2 weeks (Figure 2c). His grandmother was tested negative for both RDT and DPP[®] Syphilis Screen and Confirm Assay.

Case 2

Case 2 was a 6-year old, male, from the Aizo ethnic group, 2nd of a sibling of 2 children, living in the village of Gandaho in the Subdistrict of Dodji Bata in Zè with his father. He was 110 cm tall, weighed 17 kg and was not schooled. He was accompanied by his father for skin lesions that had been growing for about 6 months. These lesions were painless, did not itch and were not accompanied by fever. There was no notion of taking medication or prior medical consultation for the lesions. There was notion of similar skin lesion on his sister (case 3 presented below). His father had no suspected lesion.

The physical examination revealed multiple small ulcers on his both lower limbs and on his abdomen (Figure 3a). The RDT and the “DPP[®] Syphilis Screen and Confirm Assay” performed were both positive, thus confirming clinical active yaws case (Figure 3b). The RPR test performed on venous blood samples at the laboratory of CDTUB Allada was positive. He was treated promptly with 750 mg oral Azithromycin and full recovery was achieved after 2 weeks. His father was tested negative for both RDT and “DPP[®] Syphilis Screen and Confirm Assay”.

Case 3

Case 3 was an 8-year old, female from the Aizo ethnic group. She was 126 cm tall, weighed 20 kg and was not schooled. She is the older sister of the case 2 and lived in the village of Gandaho in the Subdistrict of Dodji Bata in Zè. She was accompanied by her father for skin ulcers on her both lower limbs which had been growing for about 3 months. These lesions were painless, did not itch and were not accompanied by fever. There was no notion of taking medication or prior medical consultation. The physical examination revealed multiple small ulcers on her both lower limbs (Figure 4a). The RDT and “DPP[®]

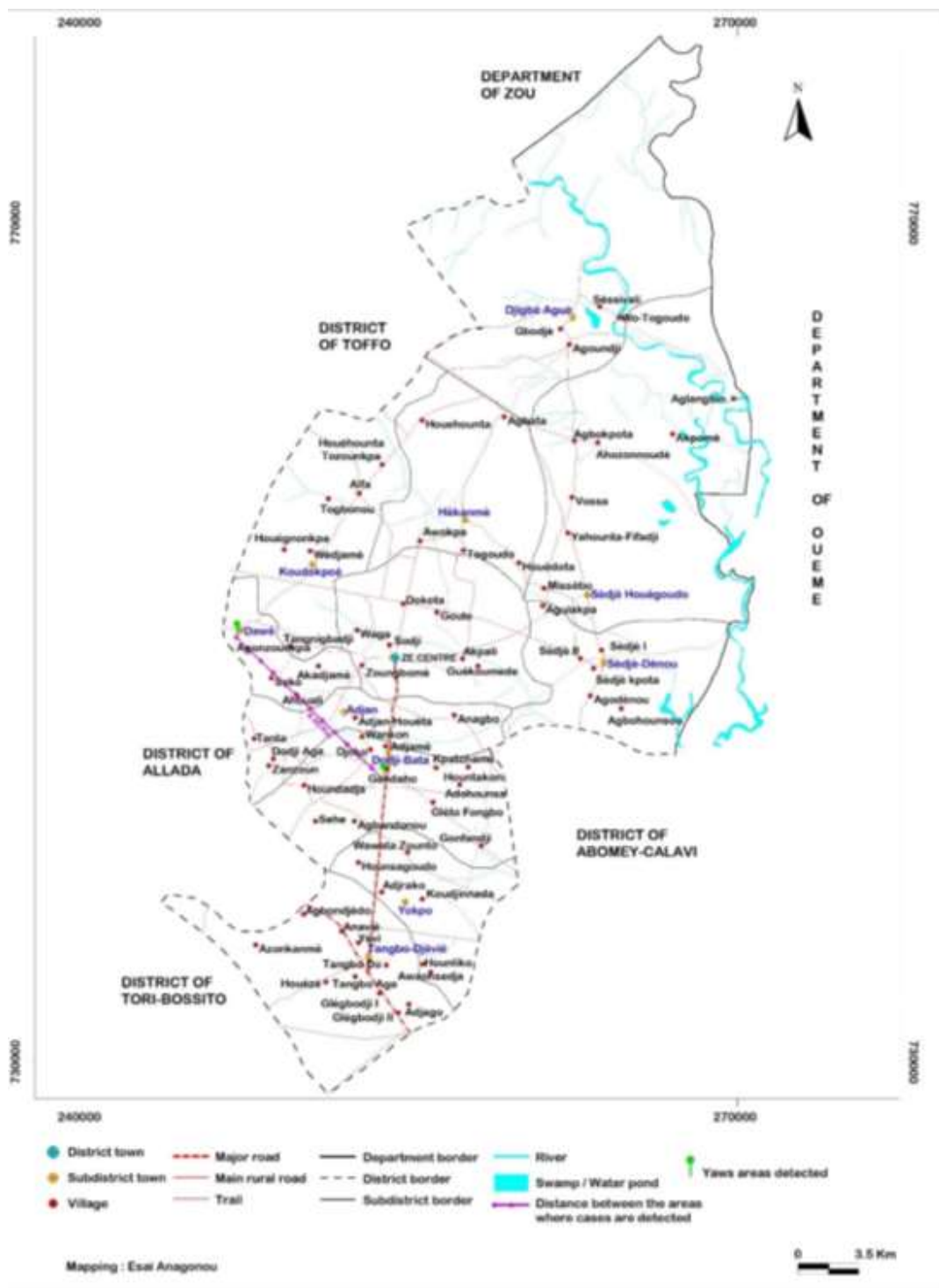


Figure 1. Distribution of the four cases in Zè district, Southern Benin.

Syphilis Screen and Confirm Assay” were both positive, thus confirming a clinical active yaws case (Figure 4b).

The RPR test performed on venous blood samples at the laboratory of CDTUB Allada was positive. She was

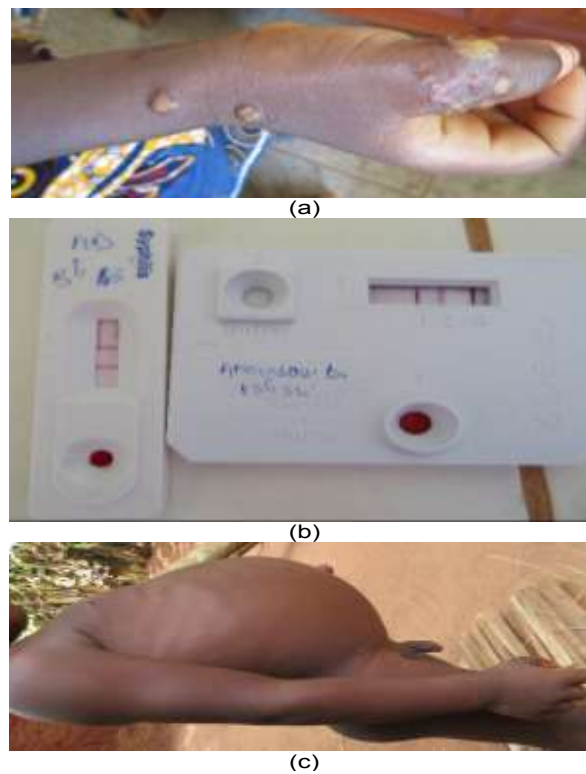


Figure 2. (a) Initial lesion of case 1 (b) RDT and DPP results from case 1 (c) Image of case 1 two weeks after treatment.

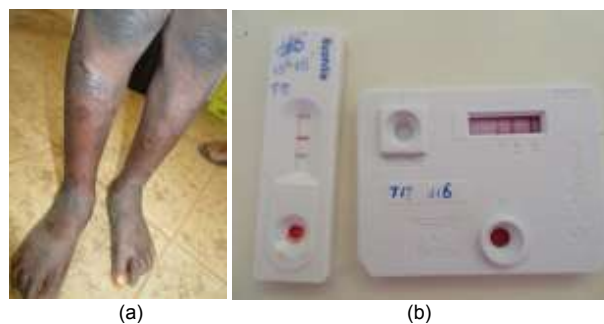


Figure 3. (a) Initial lesion of case 2 (b) RDT and DPP results from case 2.

promptly treated with 750 mg of oral Azithromycin and full recovery was achieved within 2 weeks (Figure 3c).

Case 4

Case 4, from the Aizo ethnic group, was a 6-year old male, 2nd in a sibling of 4 children, who lived in the village

of Agonzoukpa in the Subdistrict of Dawé in Zè. He was 112 cm tall, weighed 16 kg and in Class 2 of primary school. He was accompanied by a community volunteer for skin lesions on his upper limb and buttock that had been growing for about 3 months. These lesions were painless, did not itch and have not been accompanied by fever. There was no notion of taking medication or prior medical consultation. There was however the notion of an

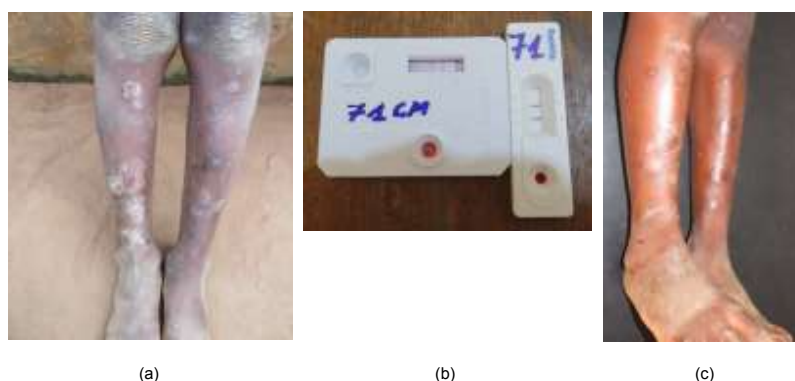


Figure 4. (a) Initial lesion of case 3 (b) RDT and DPP results from case 3 (c) Image of case 3 two weeks after treatment.

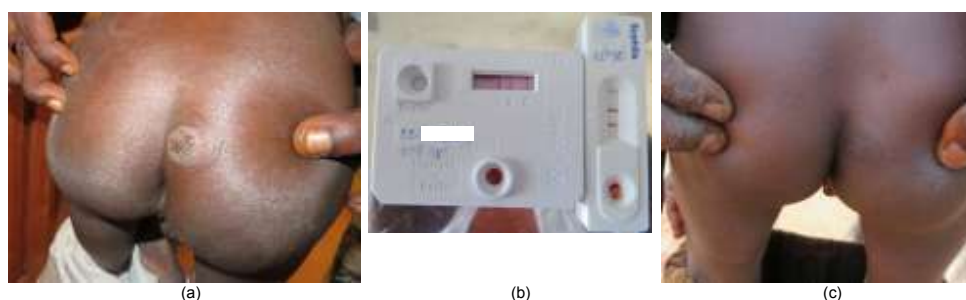


Figure 5. (a) initial lesion of case 4 (b) RDT and DPP results from case 4 (c) Image of case 4 two weeks after treatment.

unsuccessful use of phytotherapy. His siblings and direct parents had no suspected lesion on their skin and there was no notion of contact with the above cases.

The physical examination revealed two papillomas, one on the right wrist and the other on the buttock (Figure 5a). The RDT and “DPP[®] Syphilis Screen and Confirm Assay” were both positive thus confirming a clinical active yaws case (Figure 5b). The RPR test carried out on venous blood samples at the laboratory of CDTUB Allada was positive. His siblings and direct parents were tested negative for both RDT and “DPP[®] Syphilis Screen and Confirm Assay”. He was promptly treated with 500 mg of oral Azithromycin and full recovery was achieved within 2 weeks (Figure 5c). The clinical, epidemiological and biological characteristics of the four cases are presented in Table 1.

Ethical statements

The four cases were found during a field mass medical consultation held from October to December 2018 in the Department of Atlantique, Southern Benin.

The field mass medical consultation received the approval of the Ministry of Health in Benin as a routine field activity of the national control programme for leprosy and Buruli ulcer which is in charge of yaws surveillance in Benin. The activity received approval of the local authorities who were involved in community mobilization. Participation in the activity was free of charge and irrespective of age and gender. Participant received explanations on the activity and gave oral consent before participating in the activity. Medical consultation and the treatment given were free of charge.

DISCUSSION

The four cases were detected 36 years after the last documented cases in Benin and they have not travelled to a known yaws endemic area. Only one case is schooled. The district of Zè shared borders with the districts of Adjohoun and Bonou in the Department of Ouémé where yaws cases were notified in 1982 (Baudon and Houssou, 1984). Yaws could be endemic in the district of Zè at that period as any action was taken for

Table 1. Epidemiological and clinical characteristics of the four yaws cases in Zè, Southern Benin.

Case	Age (years)	Sex	Type of lesion	Number of lesion	Location	Delay (day)	Village	Sub-district
Case 1	4	M	Papilloma	Multiple	Upper limb	150	Gandaho	Dodji Bata
Case 2	6	M	Ulcer	Multiple	Lower limbs Abdomen	150	Gandaho	Dodji Bata
Case 3	8	F	Ulcer	Multiple	Lower limbs	90	Gandaho	Dodji Bata
Case 4	6	M	Papilloma	2	Upper limb Buttock	90	Agonzounkpa	Dawé

yaws eradication. Thus, the transmission could continue in the district of Zè and yaws lesions in the district could have been misdiagnosed since yaws was not on surveillance and the health workers had no background in yaws disease. According to the communities of the two villages, yaws-like lesions are common in the community and people get healed after auto medication using antibiotic or herbal medicine. Using frequently oral azithromycin for their patients, health workers would have treated successfully yaws lesions without knowing that it was a case of yaws. This could explain the fact that there were few cases detected in 1837 people attended to during the field mass medical consultation activity.

All four cases were detected in two subdistricts of the district of Zè. Three of the cases were from the village of Gandaho in the subdistrict of Dodji Bata and shared the same home. This attested to the known human-to-human transmission of the disease. The cases were between 4 and 8 years old and three of them were between 6 and 8 years old, the age group reported in the literature as the most vulnerable for the disease (World Health Organization, 2012). None of the cases had visited the health center prior to being attended to by the field medical consultation team. The remoteness of the village of Gandaho from the health center in the subdistrict of Dodji Bata could explain why the three cases of the village did not visit the health center. For the 4th case, this could be explained by the absence of health facilities in the subdistrict of Dawé where he lived. He was brought by a community volunteer from the village of Agonzounkpa who had benefited from the training on the integrated screen and case management of NTDs organized by the CDTUB of Allada before the field mass medical consultation campaign. This attested to the importance of community volunteers in the detection of yaws cases as it has been shown in the detection of Buruli ulcer (Barogui et al., 2014).

A limitation of this case report is that we were not able to confirm our cases by protein chain reaction (PCR) for *Treponema pallidum pertenuis*, which remains the only test that can differentiate yaws from the other endemic treponemal diseases. The non-treponemal tests can also give rise to false positives in patients with other disorders, including malaria, leprosy, and rheumatological diseases

(Mitjà et al., 2013). However, based on the clinical manifestations, the rapid diagnosis test results, the age group of the cases, the past history of yaws in Zè (Baudon and Houssou, 1984) and the fact that there is no history of pinta and bejel in Benin (Mitjà et al., 2013; Marks et al., 2014), it is evident that the cases described are cases of yaws.

Conclusion

The cases of yaws described in this report confirmed the resurgence of yaws in Benin in general and in the district of Zè in particular. Buruli ulcer, leprosy and mycetoma are also endemic in this district. This calls for urgent action in the district of Zè and in the bordered districts to ensure the eradication of the disease. Based on the Morges strategy of yaws eradication, it is necessary to evaluate the importance of yaws prevalence in the district of Zè by screening all children under 15 years living in the area and carrying out a total community treatment or a total targeted treatment with oral azithromycin (World Health Organization, 2012). These activities could be extended to the other districts which share border with the district of Zè. Surveillance must continue in the other districts in the south of Benin in order to identify other yaws foci.

CONFLICT OF INTERESTS

The authors have not declared any conflict of interests.

ACKNOWLEDGEMENT

This study is partially supported by “Project Rationale approach to effective wound care in West Africa” UBS Foundation (www.ubs.com/optimus) and Anesvad Foundation (<http://www.anesvad.org>).

REFERENCES

- Asiedu K, Amouzou B, Dhariwal A, Karam M, Lobo D, Patnaik S, Meheus A (2008). Yaws eradication: past efforts and future

- perspectives. *Bulletin of the World Health Organization* 86(7):499-499A.
- Barogui YT, Sopoh GE, Johnson RC, de Zeeuw J, Dossou AD, Houezo JG, Asiedu K (2014). Contribution of the community health volunteers in the control of Buruli ulcer in Benin. *PLoS Neglected Tropical Diseases* 8(10):3200.
- Barogui YT, Diez G, Anagonou E, Johnson RC, Gomido IC, Amoukpo H, Asiedu K (2018). Integrated approach in the control and management of skin neglected tropical diseases in Lalo, Benin. *PLoS Neglected Tropical Diseases* 12(6):6584.
- Baudon D, Houssou B (1984). Le Niveau de l'Endémie Pianique dans le Sud du Bénin en 1982'. *Annales de la Société belge de Médecine Tropicale* 64:397-402.
- Fitzpatrick C, Asiedu K, Sands A, Pena TG, Marks M, Mitja O, Van der Stuyft P (2017). The cost and cost-effectiveness of rapid testing strategies for yaws diagnosis and surveillance. *PLoS Neglected Tropical Diseases* 11(10):e0005985.
- Knauf S, Liu H, Harper KN (2013). Treponemal infection in nonhuman primates as possible reservoir for human yaws. *Emerging Infectious Diseases* 19(12):2058-2060.
- Marks M (2016). Yaws: towards the WHO eradication target. *Transactions of the Royal Society of Tropical Medicine and Hygiene* 110(6):319-320.
- Marks M, Solomon AW, Mabey DC (2014). Endemic treponemal diseases. *Transactions of the Royal Society of Tropical Medicine and Hygiene* 108(10): 601-607.
- Mitjà O, Hays R, Ipai A, Penias M, Paru R, Fagaho D, Bassat Q (2012). Single-dose azithromycin versus benzathine benzylpenicillin for treatment of yaws in children in Papua New Guinea: an open-label, non-inferiority, randomised trial. *The Lancet* 379(9813):342-347.
- Mitjà O, Marks M, Konan DJ, Ayelo G, Gonzalez-Beiras C, Boua B, Obvala D (2015). Global epidemiology of yaws: a systematic review. *The Lancet Global Health* 3(6):324-331.
- Mitjà O, Asiedu K, Mabey D (2013). 'Yaws'. *The Lancet* 381:9868 (2013):763-773.
- Mitjà O, Marks M, Konan DJ, Ayelo G, Gonzalez-Beiras C, Boua B, Obvala D (2015). Global epidemiology of yaws: a systematic review. *The Lancet Global Health* 3(6):324-331.
- Narain JP, Jain SK, Bora D, Venkatesh S (2015). Eradicating successfully yaws from India: The strategy & global lessons. *The Indian Journal of Medical Research* 141(5):608.
- World Health Organization (WHO) (2008) Elimination of yaws in India. *Weekly Epidemiological Record* 83(15):125-132.
- World Health Organization (WHO) (2012) 'Eradication of yaws - the Morges Strategy', *Weekly Epidemiological Record* 87(20) :189-200.
- World Health Organization(WHO) (2015). Eradication of Yaws in India. *Weekly Epidemiological Record* 90(16):161-168.
- World Health Organization(WHO) (2018a). Eradication of yaws: A guide for programme managers. Geneva. doi: Licence: CC BY-NC-SA 3.0 IGO.
- World Health Organization (WHO) (2018b). Eradication of yaws: Procedures for verification and certification of interruption of transmission. Geneva. doi: Licence: CC BY-NC-SA 3.0 IGO.
- World Health Organization (WHO) (2018c). Report of a global meeting on yaws eradication surveillance, monitoring and evaluation', in *Global Meeting on Yaws Eradication Surveillance, Monitoring and Evaluation*. Geneva, Switzerland 37 p.
- World Health Organization (WHO) (2018d). Results of the 2017 global WHO survey on yaws. *Weekly Epidemiological Record* 93(33):417-428.